REVIEW ARTICLE

VIRTOPSY : FUTURE OF AUTOPSY ?

Author:

[1]Dr. Sudharani
[2] Dr. Pradeesh Sathyan
[3]Dr. Latha Mary Cherian
[4] Dr. Sabu Paul

ABSTRACT

Virtopsy which literally means virtual autopsy, a scalpel-free procedure of autopsy subsequently developed into a multitool documentation and analysis research project, combining 3D body surface imaging methods with merged CT/magnetic resonance imaging (CT/MRI) data and 3D shape analysis. It is a simple, non-invasive procedure to record the surface and internal features of the deceased. As virtopsy involves preserving the records, it is immensely helpful for future correlations. This technique is a new development in the field of forensic sciences, and its acceptability in the court of law is yet to be proved. Scientific rationale and practical merits of virtopsy salutes and respects the religious and emotional sentiments of various ethnic groups. The present article is an overview of this emerging technique.

Key words: Virtopsy, Imaging methods, Forensic sciences.

J Ind Dent Assoc Kochi 2022;4(2):10-9.

[1]Post Graduate Student
Dept. of Oral Pathology and Microbiology
Government Dental College,
Kottayam, Kerala

[2]Assistant Professor
Dept. of Oral Pathology and Microbiology
Government Dental College
Kottayam, Kerala

[3]Professor and Head
Dept. of Oral Pathology and Microbiology
Government Dental College
Kottayam, Kerala

[4]Associate Professor
Dept. of Oral Pathology and Microbiology
Government Dental College
Kottayam, Kerala

Corresponding author
Dr. Sudharani
Post Graduate Student
Dept. of Oral pathology and Microbiology
Government Dental College,
Kottayam, Kerala. Pin 686008
E-Mail - sudhabajantri95@gmail.com
Phone - 9663055009

INTRODUCTION

Death is an inevitable part of life and at few occasions scientific examination of bodies after death becomes mandatory[1]. Forensic science is a multidisciplinary science amalgamating criminalistics, engineering science, general jurisprudence, odontology, pathology/biology, psychiatry and behavioural science, questioned documents, toxicology, and physical anthropology. On the other hand, forensic medicine deals with the examination and identification of relevant medical data in both living and dead [2].

The traditional procedures of autopsy included dissection, interpretation and cataloguing and the data gathered from the examination was then put together for arriving at the conclusion. The dead body was then delivered for the last rites to be performed. However, the mutilations involved in the procedure often left the distressed family disturbed. These pitfalls led to the birth of virtopsy[3].

Virtopsy is a minimally invasive, observer-independent new-age approach in postmortem examination[4]. Virtopsy is a virtual substitute to a traditional autopsy, conducted with scanning and imaging technology. The name is a portmanteau of 'virtual' and 'autopsy' and is a trademark inscribed to Prof. Richard Dirnhofer (de), the former head of the Institute of Forensic Medicine of the University of Bern, Switzerland [5].

The non-invasive nature of virtopsy is its salient feature, offering many advantages over conventional gross autopsy. The resultant advent of virtopsy into forensic pathology appraisal, therefore, has been a necessary development[6].

Virtopsy represents not only the first step toward a better obtaining of information regarding death causes, lesions types, etc., through modern technologies but also an alternative that ensures the right to body integrity, to intimacy, and assigning an intrinsic value to the human body. At the same time, virtopsy avoids social stigma, whose huge prejudices would exhibit on the family members and on the deceased person, impacting the image of his life. Although virtopsy is advanced and has many benefits, it in itself is not entirely free from demerits[7].

This article reviews on virtopsy where in various articles were tracked down through web search, relevant data were selected, extracted and summarized here.

History:

A question "The autopsy: Do we still need it?" released by a journal "Chest" in 1970 led to an initiation of new paths and alternative ways for autopsy[8]. Imaging techniques were suggested as the most important pathway and was supported by the establishment of organizations like the Society of Imaginological Autopsy (Japan), the Institute of Forensic Medicine (Denmark), the Headquarters of Medical Examinations of the Armed Forces of the United States of America and the Victorian Institute of Pathology (Australia)[9]. In the nineties, the Institute of Forensic Medicine of the University of Bern, Switzerland, started to document on the properties of the human body in a concrete, objective and non-invasive way. This arose the creation of a new discipline, designated as "Virtopsy", a virtual project of autopsy[2]. In this context, the idea of the objective and non-invasive documentation of the body lies in the observation of the anatomical structures through computed tomography (CT), magnetic resonance (MRI) and micro radiology devices. The computed tomography images of the observed structures were developed into 3D reconstructions by using specific software (e.g. Tera Recon Aquarius NET®, Foster City, California, United States of America). Another part of the documentation deal with the body surface recording, performed by forensic photogrammetry and 3D optical scanning[9].

The keystones of Virtopsy are –Three-dimensional (3D) surface scanning 3D/computer aided design photogrammetry, Multi-slice computed tomography (MSCT), Magnetic resonance imaging (MRI), MRI spectroscopy.

Procedure of Virtopsy

Virtopsy contains the following tools[9]:

- 3D surface scan using 3D photogrammetry based optical surface scanner
- Post-mortem CT (PMCT) with adjuvants such as PMCT-guided biopsy (pm-biopsy and PMCT-guided angiography)
- Post-mortem MRI (pm-MRI)/MRS (magnetic resonance spectroscopy).
- 3D facial reconstruction.

The procedure of virtopsy is based on the

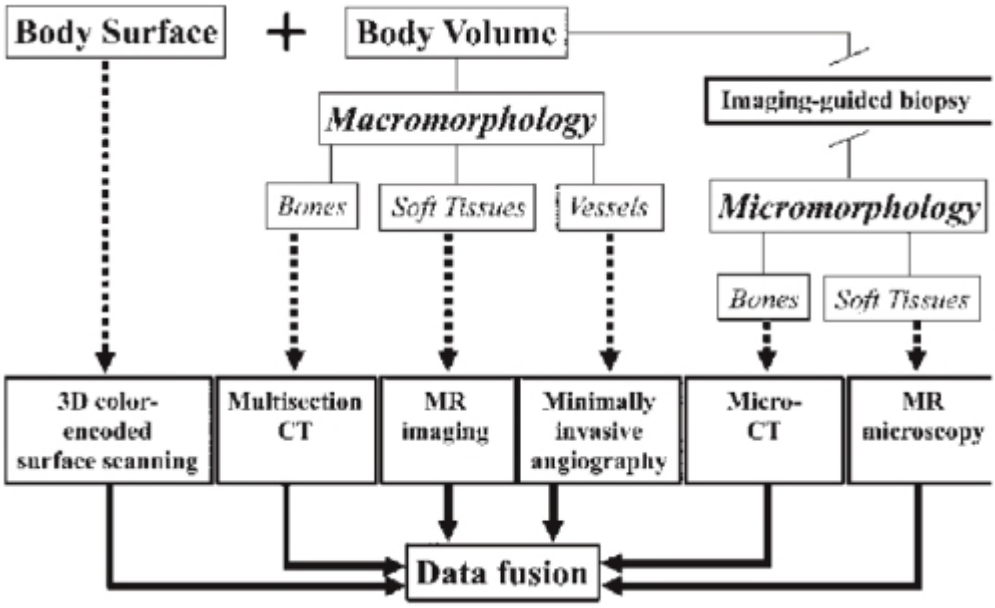

Fig. 1 : Chart illustrates the Virtopsy project, in which forensic information is acquired with various radiologic methods.
Courtesy - Dirnhofer R, Jackowski C, Vock P, Potter K, Thali MJ. Virtopsy – minimally invasive, imaging guided virtual autopsy.

principle of triangulation and an entire procedure requires approximately 30 minutes. The accuracy of virtopsy on detailing anatomical structures depends on the equipment and the settings used.

A. Arrange the corpse for autopsy

- Place small disks along the exterior of the body so that the surface scan and the interior scans could easily be lined up.
- The markers are used by the computer processors to calibrate the exterior scan of the corpse and match with internal imaging processes.
- Virtobot was developed at university of Bern. Using it, interpersonal inaccuracies can be avoided. It scans around the dead tissue with light radiation and takes photos with high quality.

B. 3D color model of the corpse

- The scan uses stereoscopic cameras of 0.02mm resolution to capture the color image, and a projector is used to cast a mesh pattern on the body.
- The robot move over the body creating a 3D image and the process takes as little as 10seconds.

C. After surface scanning - preparing[10] for CT/MRI

- Brought to the CT and MRI workplace usually double-covered inside a blue bag through which X-rays can easily pass, in order to prevent contamination and then the body is placed on the sliding table of the CT, MRI, and MRS equipment.
- While the body is scanned, the bag will remain closed, in order to respect privacy of the dead, maintain hygiene of the surroundings and to remain undisturbed by any non-forensic personnel in the room (Figure 2).

D. CT and MRI/MRS

- A corpse is subjected to CT scan, a procedure that takes upto 20 seconds and obtains up to 25,000 images.
- Each image is a slice or cut through the body. Further, the corpse is also subjected to MRI and MRS scans.

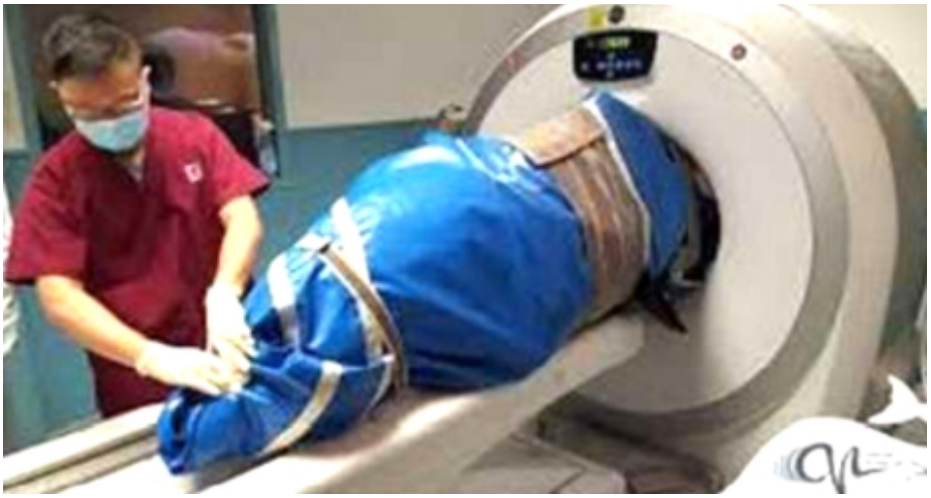

Fig.2 : Blue bag containing the corpse during scanning
Courtesy - Virtopsy: Digital Era of Autopsy, Shreshta Sathish.

E. Combining the data

- Interior and surface scans are fed to powerful desktop computers where in data are combined, further furnished using computer aided drafting-style programs and ultra-powerful graphics processors.
- In a short interval as 10 min, crisp, detailed images of bone and tissue are reconstructed using powerful desktop computers, from the data representing thin X-ray slices of the body.
- Different tissues, foreign objects (such as bullets) and bodily substances absorb the scanner's X-rays in varying amount and the different absorption levels are supplied into a 3D visualization of different colors and opacities.
- The computer can allot the density differences of any color, but this is often standardized as
  - Blue for air pockets,
  - Beige for soft tissues,
  - Red for blood vessels,
  - and White for bones.

F. 3D Forensic Facial Reconstruction

- Computerized 3D FFR: 3D computerized models are constructed using manual clay model techniques.
- Computerized systems
  - 3D animation software: to replicate the face onto the skull
  - Sensable Technologies
  - Phantom Desktop TM Haptic Device
  - Virtual sculpture system with haptic feedback[11].

Virtopsy table

This is a large touch-sensitive liquid-crystal display screen represents the operating table displaying the image of the body. This device was developed by Dr. Anders Persson[11]. (Figure3).

Practice of Virtopsy

Virtobots

virtopsy uses an all-in-one machine called "Virtobot" which integrates the four imaging tools of virtopsy. This machine will allow combined surface and body volume data addition within a single 3D space, making present-day data fusion techniques dispensable. (Figure 4)

Virtomobile

Virtobot is a gigantic machine making its use in the sites of mass disaster ineffective. This led to the requirement of a more compact device for practice of virtopsy. Thus, virtomobile was conceived. It is a variety of Virtobot mounted on a trailer which can be easily transported to the site of disaster[12].

Fig. 3 Virtopsy table - Large touch-sensitive liquid-crystal display screen represents the operating table displaying the image of the body
Courtesy- Virtopsy: The Digital Era of Autopsy ,Shreshta Sathish.

Applications:

For identification of individuals

Dental identification procedures often deal with comparison between post-mortem and ante mortem data, dental deoxyribonucleic acid techniques and development of dental post-mortem victim details. Post-mortem dental data are compulsory for dental identification and these are obtained principally by visual examination. But visual examination is arduous in victims with charred bodies and damaged oral cavities. In such cases, virtopsy becomes a very quick, reliable way for getting post-mortem records[13.]

Smith et al. reported a case of positive identification of a deceased individual which was achieved by performing a CT scan on an unidentified cranium and comparing multiple landmarks, images with corresponding features in an ante mortem CT scan of a missing individual. The result revealed that they were exactly the same on both CT scans, confirming the identity of the missing person [14].

For toxicological examination

Virtopsy can be used as a tool to determine the death of an individual in cases of drug abuse [13].

Fig. 4
A representative image of the VIRTOBOT system. Courtesy: Louise Murray, Biomedical Picture of the Day (BPoD). Managed by the MRC London Institute of Medical Sciences

Virtopsy in road traffic accident

Aghayev reported a case series of three cases of fatal blunt head injury using post-mortem MSCT and MRI that revealed substantial hard and soft tissue injuries of the head and signs of high intracranial pressure along with herniation of the cerebellar tonsils. Similar findings were found in clinical autopsy, which was performed after the digital autopsy[15].

Role of virtopsy in cardiorespiratory failure from nontraumatic origin

Sohail et al. described the utility of PMCT examination in determining the cause of death among male prisoners dying in Karachi jails, and it was concluded that PMCT is as effective as dissection autopsy in recognizing pulmonary infections and natural causes of death [16].

In determining the timing of death

Virtopsy can be used to determine the timing of death by the changes seen in both MSCT and MRI in head injury cases[17].

Role of virtopsy in death due to burns

Thali et al. reported a case of a completely charred body resulted from a single motor vehicle/fixed object collision with a post-crash fire. With a help of radiological methods of MSCT and MRI it was possible to document the injuries caused by burns as well as the forensic relevant vital reactions such as air embolism and blood aspiration and they concluded that post-mortem imaging is a good forensic visualization tool with a great capacity for forensic documentation and examination of completely charred bodies[18].

Role of virtopsy in gunshot injuries

Thali MJ et al. reported a case series of eight gunshot victims scanned by MSCT and MRI; the data from these imaging techniques were post processed in a workstation, interpreted with subsequent correlation of findings from classical autopsy. The spiral CT and MRI examinations with the subsequent two-dimensional multi-planar reformation and 3D shaded surface display reconstruction the entire gunshot created complex skull fractures and brain injuries (deeply-driven bone splinters and wound channels) could be documented in complete graphic detail [19].

Virtopsy in drowning deaths

Plattner reported a case of drowning in which the findings of a massive vital decompression with pulmonary barotrauma and lethal gas embolism were identified in the radiological images[20].

Virtopsy in hanging or manual strangulation

Case series of nine persons who died from hanging or manual strangulation was reported by Yen K et al. They described a post-mortem MSCT and MRI reports of the deceased. The neck findings were compared with those discovered during forensic autopsy. In addition, two living patients underwent imaging and clinical examination following severe manual strangulation and near-hanging, respectively. The report concluded that MSCT and MRI revealed strangulation signs concordantly with forensic pathology findings[21].

Virtopsy for age and gender determination

Sexually dimorphic bones that include pelvic bones such as the os sacrum are used to determine the gender in forensic practice. PMCT scan provides an easy and fast method for depicting and measuring bone structures prior to elaborative autopsy preparations[22].

Medico-legal autopsy in Covid-19 deaths is a high-risk procedure and should be avoided where ever possible[23]. 'Virtopsy' has been suggested as an effective alternative to high-risk traditional autopsy procedure in pandemic situation like Covid-19[24].

THE VIRTUAL DENTAL AUTOPSY PROJECT (VIRDENTOPSY)

The identification process of unidentified human remains should always adhere with best practices in human identification, which should always comprise a complete dental

VIRDENTOPSY™

UNIVERSITÀ DEGLI STUDI DI TORINO

Fig.5 : Virdentopsy™ registered brand (Class 44).
Courtesy - Silver, E.W.; Souviron, R.R. Postmortem records. The dental autopsy. In Dental Autopsy; Silver, E.W., Souviron, R.R., Eds.; CRC Press: Boca Raton, FL, USA

autopsy even when no forensic odontologists are available onsite. Based on this hypothesis, The Human Identification Laboratory and the medico-legal section of the University of Turin started a research project in 2020 Furthermore, teleconsultation in medicine and dentistry, especially during the COVID-19 pandemic[25] and potential risk of infection[26], can also be applied in forensics, and specifically in the human identification process. This allows forensic pathologists to perform the autopsy procedure without compromising on the technical inputs of forensic odontologists. Currently, there are few institutions worldwide that have recognized the feasibility of remote dental autopsy[27,28] but none are currently offering teleconsultations in forensic odontology for the purpose of human identification or considering offering this service on a humanitarian basis. The project comprises research topics such as pathology, anthropology, odontology and archeology under the umbrella of human rights of the dead and humanitarian forensic odontology[27,29,30]. The term VIRDENTOPSY blends the terms "virtual" and "dental autopsy". It is a registered brand (Figure 5) with a dedicated website[30] in order to offer a remote forensic odontological assessment of post-mortem dental data of unidentified human remains. Virdentopsy provides facilities for the systematic collection of post-mortem dental data performed by forensic pathologists, dentists with no forensic background, dental hygienists with a forensic background, or other forensic operators authorized in the mortuary. These operators perform the dental and intraoral collection of postmortem dental data (also in livestreaming), following what is usually performed by forensic odontologists in the preliminary dental examination of human remains, which is one of the stages of a traditional dental autopsy[31]. Data can be passed on to the human identification laboratory, where one or more forensic odontology consultants could evaluate the data received and provide charting and the dental autopsy report[31]. Provisions on the unidentified human remains consist of the following data collection:

I. 2D or 3D video recording of the dental arches and oral cavity, using intraoral camera or smartphones (Figure 6).

ii. Photographic collection of the dental arches.

iii. Photogrammetry of the dental arches using an intraoral scanner (Figure 7).

iv. 3D scanning of jaws and skull.

v. Intraoral radiographic collection using digital sensors.

vi. Any radiographic imaging of the skull (Panoramic images, OPG, TC scans, if available).

vii. Live streaming using smartphone and smart glasses (Figure 8).

By registering on the Virdentopsy website, it will be possible to choose a type of assessment, either a single unidentified human remains, or an assessment within a DVI procedure, and decide if a primary or secondary expert opinion is required. Quality control checks would be carried out on the received data. The service is remunerated or pro-bono depending on the applicant entity. This forensic service will also be available for age estimations of living individuals and for hands-on training sessions of forensic odontology courses[32].

Advantages of virtopsy:

1. It is a non-invasive and a scalpel free imaging technology.
2. It has a digital storage facility over years or decades and even transferrable over the web for second opinion.
3. It is an ethical evolution which serves better acceptance for the relatives of the deceased and also by certain religious customs where incisions are not recommended after death.
4. No hazard of infections from the blood or other tissue fluids as there is no mutilation of the body.

Fig. 6 : Operator using smart glasses to observe and record dental features on the mandible.
Courtesy- Nuzzolese E. VIRDENTOPSY: Virtual Dental Autopsy and Remote Forensic Odontology Evaluation

Fig. 7 Post-mortem photogrammetry collection of upper dental arch using an intraoral scanner.
Courtesy- Nuzzolese E. VIRDENTOPSY: Virtual Dental Autopsy and Remote Forensic Odontology Evaluation

5. It is less time consuming and body can be released immediately after the scanning[1].
6. It is extremely efficient in studying wounds and helps matching of the probable weapon. This can be studied without disturbing the body architecture[33].

Disadvantages of Virtopsy:

1. It is not possible to differentiate all the pathological conditions with this technique.
2. It is associated with insufficient data base when compared to conventional autopsy.
3. It exhibits dilemma in distinguishing ante mortem/postmortem artifacts, color changes and establishment of infection status.
4. Infrequently small tissue injury may be missed[33].
5. The initial investment for the equipment required may not be feasible in developing countries[4].

Emerging Applications of Virtopsy:

I. Volume analysis software used in virtopsy helps in accurate estimation of mass of internal organs[13].

ii. Post-mortem angiography is a virtopsy technique that is helpful in visualization of the cardiovascular system that includes infusion of contrast medium with the aid of peristaltic pump and contrast medium[13].

iii. Robotic virtual autopsy is a multifunctional system that can perform automatic post-mortem and three dimensional surface scanning which qualitatively increase the improvement in the outcome of forensic investigations. The robotic virtual autopsy also helps in detecting the change in color of tissue[13,34].

Conclusion

Virtopsy is a non-invasive and a scalpel free imaging technology. This technique allows for the permanent preservation of the document of proof, regardless whether the victim is dead and undergoing post-mortem or surviving. In comparison to other methods, imaging techniques are able to capture the findings at the moment of investigation without causing any damage and provides better analyses. It can also be used in cultures and situations where autopsy is not supported by different religions or by family members. Virtual autopsy is a new development in the field of investigations of death, and its acceptability in the court of law is yet to be proved. We can hope that in near future, we all will be accustomed to some kind of virtual autopsy or non- invasive autopsy technique which will be beneficial for the courts as well as the autopsy surgeons and the relatives of the deceased.

Fig. 8:
Live streaming images observed remotely from a forensic odontologist
Courtesy- Nuzzolese E. VIRDENTOPSY: Virtual Dental Autopsy and Remote Forensic Odontology Evaluation

REFERENCES

1. Yogish P, Yogish A. Virtopsy: New phase in forensic odontology. Int J Dent Health Sci. 2015;2:1548-5.
2. Cha JG, Kim DH, Kim DH, Paik SH, Park JS, Park SJ, Lee HK, Hong HS, Choi DL, Yang KM, Chung NE. Utility of postmortem autopsy via whole-body imaging: initial observations comparing MDCT and 3.0 T MRI findings with autopsy findings. Korean journal of radiology. 2010 Aug 1;11(4):395-406.
3. Rosário Junior AF, Souza PH, Coudyzer W, Thevissen P, Willems G, Jacobs R. Virtual autopsy in forensic sciences and its applications in the forensic odontology. RevistaOdontoCiência. 2012;27:5-9.
4. Joseph TI, Girish KL, Sathyan P, Kiran MS, Vidya S. Virtopsy: An integration of forensic science and imageology. Journal of Forensic Dental Sciences. 2017 Sep;9(3):111.
5. Thali MJ, Yen K, Schweitzer W, Vock P, Boesch C, Ozdoba C, Schroth G, Ith M, Sonnenschein M, Doernhoefer T, Scheurer E. Virtopsy, a new imaging horizon in forensic pathology: virtual autopsy by postmortemmultislice computed tomography (MSCT) and magnetic resonance imaging (MRI)-a feasibility study. Journal of forensic sciences. 2003 Mar 1;48(2):386-403.
6. Yucong W, Haibiao Z, Ran L, Haidong Z, Dong Z, Xu W, Tiantong Y. Application of virtopsy in forensic pathology. Journal of Forensic Science and Medicine. 2021 Jan 1;7(1):14.
7. Kumar R. Virtopsy complementing traditional autopsy. IP International Journal of Forensic Medicine and Toxicological Sciences. 2020 Aug 15;5(2):39-42.
8. Edwards JE. The autopsy: Do we still need it?. Chest. 1970 Feb 1;57(2):113-4.
9. Dirnhofer R, Jackowski C, Vock P, Potter K, Thali MJ. Virtopsy – minimally invasive, imaging guided virtual autopsy. Radio Graphics 2006;26:1305-33.
10. Soltanzadeh L, Imanzadeh M, Keshvari H. Application of robotic assisted technology and imaging devices in autopsy and virtual autopsy. International Journal of Computer Science Issues (IJCSI). 2014 Jul 1;11(4):104.
11. Sathish S. Virtopsy: The Digital Era of Autopsy.
12. Rajendran R, Sivapathasundharam B. Forensic Odontology. Shafer's Textbook of Oral Pathology. 7th ed. Elsevier India; 2012. p 879-907.
13. Tejaswi KB, Periya EA. Virtopsy (virtual autopsy): A new phase in forensic investigation. Journal of Forensic Dental Sciences. 2013 Jul;5(2):146.
14. Smith DR, Limbird KG, Hoffman JM. Identification of human skeletal remains by comparison of bony details of the cranium using computerized tomographic (CT) scans. Journal of Forensic Science. 2002 Sep 1;47(5):1-3.
15. Aghayev E, Yen K, Sonnenschein M, Ozdoba C, Thali M, Jackowski C, Dirnhofer R. Virtopsy post-mortem multi-slice computed tomograhy (MSCT) and magnetic resonance imaging (MRI) demonstrating descending tonsillar herniation: comparison to clinical studies. Neuroradiology. 2004 Jul;46(7):559-64.

16. Sohail S, Mirza FH, Khan QS. Postmortem computed tomography for diagnosis of cause of death in male prisoners. JPMA. The Journal of the Pakistan Medical Association. 2010;60(1):4.

17. Pohlenz P, Blessmann M, Oesterhelweg L, Habermann CR, Begemann PG, Schmidgunst C, Blake F, Schulze D, Püschel K, Schmelzle R, Heiland M. 3D C-arm as an alternative modality to CT in postmortem imaging: Technical feasibility. Forensic science international. 2008 Mar 5;175(2-3):134-9.

18. Thali MJ, Yen K, Plattner T, Schweitzer W, Vock P, Ozdoba C, Dirnhofer R. Charred body: virtual autopsy with multi-slice computed tomography and magnetic resonance imaging. Journal of Forensic Science. 2002 Nov 1;47(6):1326-31.

19. Thali MJ, Yen K, Vock P, Ozdoba C, Kneubuehl BP, Sonnenschein M, Dirnhofer R. Image-guided virtual autopsy findings of gunshot victims performed with multi-slice computed tomography (MSCT) and magnetic resonance imaging (MRI) and subsequent correlation between radiology and autopsy findings. Forensic science international. 2003 Dec 17;138(1-3):8-16.

20. Plattner T, Thali MJ, Yen K, Sonnenschein M, Stoupis C, Vock P, Zwygart-Brugger K, Kilchor T, Dirnhofer R. Virtopsy-postmortemmultislice computed tomography (MSCT) and magnetic resonance imaging (MRI) in a fatal scuba diving incident. Journal of forensic sciences. 2003 Nov 1;48(6):1347-55.

21. Yen K, Thali MJ, Aghayev E, Jackowski C, Schweitzer W, Boesch C, Vock P, Dirnhofer R, Sonnenschein M. Strangulation signs: initial correlation of MRI, MSCT, and forensic neck findings. Journal of Magnetic Resonance Imaging: An Official Journal of the International Society for Magnetic Resonance in Medicine. 2005 Oct;22(4):501-10.

22. Simons D, Sassenberg A, Schlemmer HP, Yen K. Forensic imaging for causal investigation of death. Korean Journal of Radiology. 2014 Apr 1;15(2):205-9.

23. Government of India, Ministry of Health & Family Welfare, DGHS (EMR Division). Covid-19: guidelines on dead body management. New Delhi: Government of India, 15 March 2020,7 p, https://www.mohfw.gov.in/pdf/1584423700568_COVID19GuidelinesonDeadbody manage ment.pdf

24. Wayne AN. Covid-19–an example of induced change in general practice. Medico-Legal Journal. 2020 Nov;88(1_suppl):55-.

25. Song X, Liu X, Wang C. The role of telemedicine during the COVID-19 epidemic in ChinaExperience from Shandong province. Critical care. 2020 Dec;24(1):1-4.

26. Franco A, Thevissen P, Coudyzer W, Develter W, Van de Voorde W, Oyen R, Vandermeulen D, Jacobs R, Willems G. Feasibility and validation of virtual autopsy for dental identification using the Interpol dental codes. Journal of forensic and legal medicine. 2013 May 1;20(4):248-54.

27. Nuzzolese, E. Missing People, Migrants, Identification and Human Rights. J. Forensic Odontostomatol. 2012, 30 (Suppl. 1), 47–59.

28. Rutty GN, Biggs MJ, Brough A, Morgan B, Webster P, Heathcote A, Dolan J, Robinson C. Remote post-mortem radiology reporting in disaster victim identification: experience gained in the 2017 Grenfell Tower disaster. International journal of legal medicine. 2020 Mar;134(2):637-43.

29. Virdentopsy. Available online: https://www.virdentopsy.it

30. Silver WE, Souviron RR. Postmortem Records-The Dental Autopsy. InDental Autopsy 2009 Jun 23 (pp. 109-136). CRC Press.

31. Simon R. Analysis of best practices on the identification of missing migrants: Implications for the Central Mediterranean. International Organization for Migration. 2019.

32. Nuzzolese E. VIRDENTOPSY: Virtual Dental Autopsy and Remote Forensic Odontology Evaluation. Dentistry Journal. 2021 Sep;9(9):102.

33. Patowary AJ. Virtopsy: One step forward in the field of forensic medicine–A review. Journal of Indian Academy of Forensic Medicine. 2008;30(1):32-6.

34. Jeelani S, Baliah J. Nanotherapeutics in oncology: Dendrimers the nano wonder. Journal of Scientific Dentistry 2013;3:54 8.